

Complete Clinical Orthodontics: treatment mechanics: part 1

Dr. Antonino G. Secchi introduces the concepts of treatment mechanics within the CCO System™ to correct malocclusions

The concept

Treatment mechanics has always been of tremendous interest for all practicing orthodontists. Since the beginning of the specialty, orthodontists have looked for the best, fastest, more consistent, and easiest way to achieve the orthodontic correction for our patients. This continuous quest has allowed emerging technologies to integrate, although slowly sometimes, with everyday practice until they become a routine. As a consequence, new materials, improvement in design of appliances, and innovative ideas repeatedly transform the way orthodontics is practiced. It is important for the contemporary orthodontist to be knowledgeable of current changes, to gain the benefits of such innovation. Today, after the first decade of the 21st century has already passed, orthodontic fixed appliances have experienced an interesting blend between technologies that have been around for decades such as the straight wire appliance (SWA), self-ligating brackets (SLB), and low deflection heat-activated arch wires. This integration, in my opinion, represents an improvement that, when correctly applied, facilitates the practice of orthodontics.

The main objective of this series of three articles (parts 1, 2, and 3) is to introduce the concepts of treatment mechanics within the CCO System™. Part 1 will review how the SWA integrates with SLB to produce an appliance that, when combining with specific arch wires on a specific sequence, can help the orthodontist to correct different types of

Educational aims and objectives

This article aims to introduce the CCO System for correcting malocclusions.

Expected outcomes

Correctly answering the questions on page 39, worth 2 hours of CE, will demonstrate the reader can:

- Become familiarized with the basics of the CCO System and its various stages and how it relates to the correction of malocclusions.



malocclusions. Relevant characteristics of active SLB, a newly introduced prescription (CCO Rx) along with a review of the three stages of treatment mechanics will be discussed. Part 2 will focus on bracket placement, arch coordination, leveling the occlusal plane, and vertical problems. Part 3 will focus on anchorage management in extraction cases.

The evolution of the straight wire appliance

The SWA was developed and introduced by Lawrence Andrews in 1970¹ with the idea of having an orthodontic fixed appliance that would enable the orthodontist to achieve the “six keys” of normal occlusion² in the vast majority of cases in an efficient and reliable fashion. Even though the SWA is 42 years old and has become the most common appliance concept over the past three decades, a review of some of the original concepts on which the SWA was designed, and the evolution it has gone through, are fundamental to better understanding of the beauty of this

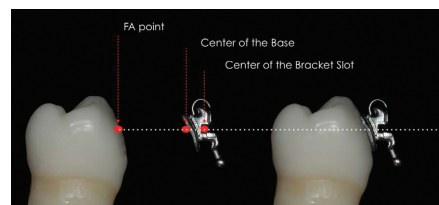


Figure 1: Shows the ideal relationship between the center of the slot, the center of the bracket base, and the reference point (middle of the clinical crown occlusogingivally along the facial long axis of the crown)

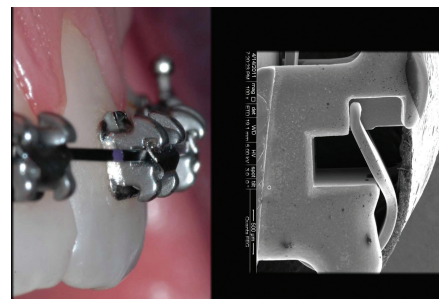


Figure 2: (A) Shows a clinical closed up of the In-Ovation R bracket with a 0.020" x 0.020" BioForce. The active clip already started pushing the wire into the slot, which will begin to express torque. (B) Shows a SEM photo of an In-Ovation R bracket, (taken at the University of Pennsylvania as part of a research by the author's research group). Bracket features such as the design of the slot and the clip can be better appreciated

appliance and the treatment mechanics.

A few features need to be present in an appliance to be considered a true SWA³. First, each bracket has to be tooth-specific and have built-in torque, tip, in/out, and, for the molars, the proper offset. Second, the torque has to be built in the base of the bracket, not in the face, and the tip in the face of the slot. These prerequisites are very important in order

Antonino G. Secchi, DMD, MS, is a clinical assistant professor and former clinical director of the Department of Orthodontics at the University of Pennsylvania. Dr. Secchi received his DMD, Certificate in Orthodontics, and a Master of Science Degree in Oral Biology from the University of Pennsylvania. He is a Diplomate of the American Board of Orthodontics and member of the Edward H. Angle Society of Orthodontists. At the University of Pennsylvania, he has developed and implemented courses on Orthodontic Treatment Mechanics, Straight Wire Appliance Systems, and Functional Occlusion in Orthodontics for postdoctoral orthodontic residents. Dr. Secchi wrote the chapter “Contemporary Mechanics Using the Straight Wire Appliance” for the latest edition of the Graber/Vanarsdall/Vig orthodontic textbook. He also received the 2005 David C. Hamilton Orthodontic Research Award from the Pennsylvania Association of Orthodontists (PAO) and the 2010 Outstanding Teacher Award from the Department of Orthodontics of the University of Pennsylvania. Dr. Secchi is the founder of the “Complete Clinical Orthodontics System” (CCO System™), which he teaches to orthodontists throughout the world. He also maintains an active orthodontic practice in Philadelphia and Devon, Pennsylvania.

to achieve proper alignment of the center of the slot, the center of the base, and the reference point (middle of the clinical crown occlusogingivally along the facial long axis of the crown) for all teeth at the completion of treatment (Figure 1). This is the only way that the desired built-in features can be properly transferred from the bracket to the tooth. Third, the base of the bracket must be contoured mesiodistally and occlusogingivally.

This has been referred to as “compound contour” base, and it allows the bracket to firmly adapt to the convexities of the labial surface of each tooth, helping the orthodontist to achieve an optimal bracket placement⁴. Andrews’ treatment mechanics in extraction cases, which was based on sliding teeth using round stainless steel wires, made him develop a series of additional brackets with different degrees of overcorrection to account for undesired tooth movement that occurs when closing spaces. For example, if a maxillary canine had to be moved distally, the canine most likely would tip and rotate distally. Therefore, he introduced more mesial tip and rotation to the canine bracket. Andrews then came out with a line of overcorrected brackets, which he called first extraction brackets^{5,6} and then translation brackets⁷. Andrews’ complete bracket system (standard and translation brackets) became less popular than expected, in part due to the large bracket inventory needed to satisfy his treatment mechanics. In the early 1980s, Ron Roth combined some of the Andrews’ standard prescription (Rx) values with some of the values found in the translation bracket Rx to come out with the “Roth setup”⁸. Filling the slot with a large stainless steel arch wire to express the Rx was one of the premises of the Roth system. The Roth Rx became one of the most popular SWA Rxs in the world.

In the 90s, McLaughlin, Bennett, and Trevisi modified the SWA Rx based on the perception that most orthodontists would finish cases with a .019”x.025” ss wire, which on a .022” slot could have up to 12° of play⁹. Among others, they increased buccal crown torque of maxillary incisors, reduced lingual crown torque of mandibular molars, and increased lingual crown torque of mandibular incisors. These modifications gave form to the MBT¹⁰.

Self-ligation becoming popular

Although the history of SLB started

many decades ago¹¹, it was not until the beginning of this century that it became a popular option. Because of the fast increase in popularity of these bracket systems, the market became a “battlefield,” and unfortunately, a lot of unsupported and often ridiculous claims in favor of some of these systems were done. This phenomenon, sort of “shut the door closed” to many clinicians who wanted to learn more about and or started using self-ligating brackets. However, at the same time, a significant number of clinicians focused on quality treatment started to use these type of appliances taking notes of all the advantages as well as possible disadvantages of them. Also, a significant number of peer-review studies became available helping to better understand SLB¹².

I was fortunate to start using SLB early in my career. I had my first experience with different types of SLB systems as a resident at the University of Pennsylvania more than 10 years ago. Since that time, I steadily increased the percentage of SLB cases in my practice up to 100%. I have studied different SLB systems, done research on them, and had the opportunity to meet and share knowledge with a great number of orthodontists around the world who use SLB systems. So, today I can say with responsibility and confidence, that there is no reason to “close the doors” to the SLB system. They definitely came to stay, and therefore, the clinician should make the effort to understand how SLB works.

Over the years, the debate between active and passive SLB has been intense.

Since active SLB is this author’s preference (Figures 2A and 2B), all the content of this article is based on this author’s experience with active SLB, specifically the In-Ovation® R and C bracket system (Dentsply GAC).

The three stages of treatment mechanics will be reviewed in detail later in this article, as well as the following advantages of active SLB at each stage of treatment mechanics. Active SLB provides complete control at each stage of treatment.

Leveling and aligning:

- The wire can be fully engaged from day one. Therefore, it provides faster alignment and correction of rotations.

- Due to the reduced resistant to sliding of SLB, the wire can easily slide through

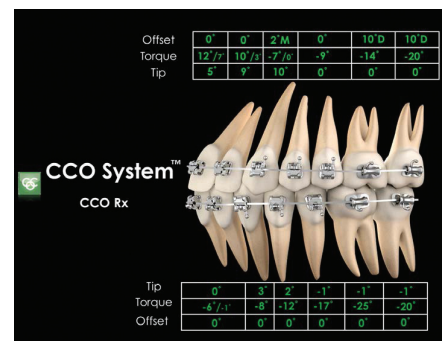


Figure 3: Shows the CCO System with all the torque, tip, and offset values for each tooth

the teeth. Then displaced teeth can move to alignment without causing unwanted tooth movement of adjacent teeth such as proclination of anterior teeth or loss of anchorage of posterior teeth.

Working stage:

- With the proper arch wire selection, the active clip provides a perfect balance between resistance to sliding and tooth control. In most cases a .019” x .025” ss wire as the working arch wire will be preferred. Teeth can easily slide through the wire mesially or distally to either open spaces or close spaces. The gentle, but constant, pressure of the clip on the wire keeps the moving tooth or teeth straight, minimizing unwanted tipping or rotation commonly seen when using conventional brackets with ligatures. The active clip pushes the .019” x .025” ss into the bracket’s slot, which allows for full torque expression¹⁰. There is no need to overcorrect the Rx for play or go up to a full size arch wire to express torque.

Finishing stage:

- Granted that all brackets have been placed in the optimal position, by the time the clinician gets to the finishing stage, each tooth should be optimally position with the right tip, torque, and offset. Finishing should not be a problem. If some fine-tuning has to be done, such as repositioning some bracket, and or placing some offsets in the wire, the active clip will help to express that correction. There is no reason why, with active SLB, an orthodontist should not be able to finish cases with quality and consistency.

The CCO Rx

The CCO Rx is a new prescription (Figure 3) developed to take full advantage of the bracket/arch wire interaction when using




Figure 4: Shows a SEM photo of an In-Ovation R bracket with a .019" x .025" ss wire, (taken at the University of Pennsylvania as part of a research by the author's research group). The springing active clip pushes the wire into the slot providing full torque expression on a .019" x .025" ss wire

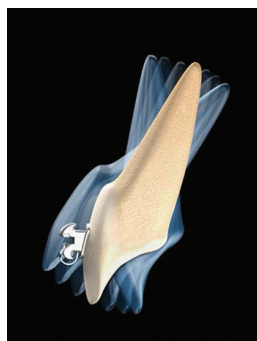

Figure 5: Highlight CCO Rx, torque for the upper incisor

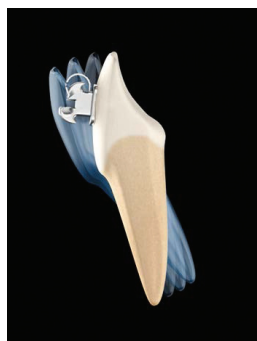

Figure 6: Highlight CCO Rx, torque for the lower incisor

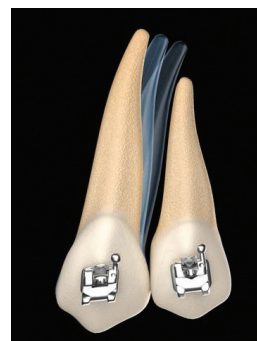


Figure 7: Highlight CCO Rx, tip for the upper canine

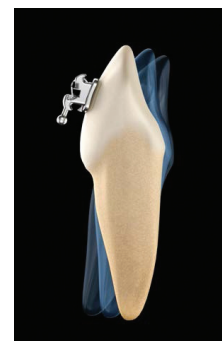


Figure 8: Highlight CCO Rx, torque for the lower canine

an active clip and to achieve optimal tooth position at the end of treatment. The goal was to offset some of the problems commonly seen with previous Rx that were meant to be used with traditional bracket system.

Rotational control

The springing capability of the In-Ovation clip, as well as its quite long mesial-distal span, facilitate the correction of all rotations within the stage of leveling and aligning. Also, the active clip favors complete engagement of the wire into the slot. This means that if the wire is not fully engaged, the clip will not close. This avoids leaving small rotations uncorrected as the wire sequence progresses. Therefore, the CCO Rx removed some of the overcorrection of the offset found in previous Rxs.

Full torque expression

The active clip of the In-Ovation brackets provides full torque expression on a .019" x .025" ss wire. The springing clip pushes the wire into the slot (Figure 4). Gick, et al.,¹³ shows that on the In-Ovation brackets a .019" x .025" ss wire can express the same amount of torque than a .021" x .025" ss wire. Therefore, some of the overcorrections of torque implemented in previous Rxs to overcome the play between the slot of the bracket and a .019" x .025" ss, do not apply when using the In-Ovation bracket, and therefore the CCO Rx removed those overcorrections.

Molar control

It is the interaction between the bracket and the wire that will transfer the values of tip, torque, and offset to the teeth.

Tubes are passive attachments. Tubes are not able to transfer the values they have, specifically torque, even if large wires are used^{14,15}. Trouble correcting the curve of Wilson of maxillary molars and excessive lingual crown torque of mandibular molars are some of the problems commonly seen by many orthodontists. Therefore, the CCO Rx has specific overcorrections for the maxillary and mandibular first and second molars to achieve proper molar control.

Incisor control

To achieve optimal torque of the maxillary and mandibular incisors is very important for both esthetics and function. It affects lip support, and consequently facial esthetics, as well as anterior coupling of the incisors, and therefore, anterior guidance. For the maxillary incisors, to achieve optimal torque is sometimes difficult due to the large amount of bone the roots must go through, specifically in extraction cases as well as class II, division II cases.

The inclination of the mandibular incisors is critical for both function and stability. Their position should be upright onto the alveolar bone. Class III camouflage, Class II mechanics, and deep curve of Spee are specifically challenging regarding the upright position of mandibular incisors over the basal bone. The CCO Rx combines proven values of torque for maxillary incisors that can be fully expressed thanks to the active clip, with a lightly overcorrection for the mandibular incisors to achieve optimal control in all kind of clinical situations. The CCO Rx is conveniently and progressively expressed throughout the stages of treatment mechanics by using specific arch wires at each stage. The ultimate goal is to

achieve optimal tooth position at the end of treatment, even before the appliance is removed.

CCO Rx highlights

The CCO Rx works as one system from second molar to second molar. The following are some of the highlight changes that were introduced:

- U1/U2: 12°/10° of torque have been selected. These values have been proven time after time to be optimal if full expression of torque is achieved. Thanks to the active clip, full expression can be achieved on a .019" x .025" ss wire. It is not necessary to increase and/or overcorrect these values (Figure 5).
- L1/L2: -6°, 0°, 0° of torque, tip, and offset have been selected. A small lingual crown torque overcorrection has been shown to help keeping the incisors in an upright position in situations such as leveling and aligning, class II correction, leveling deep curve of Spee, etc. 0° tip and 0° offset makes all four lower incisors bracket to be interchangeable facilitating bracket inventory (Figure 6).
- U3: 10° of tip has been selected as the best of both worlds. The increased mesial crown tip found in some Rx (13°) has shown undesired distal tip of the U3 root, frequently seen in X-rays. However, an upright U3 (8° or less) could compromised proper coupling with the L3 and could also decrease arch perimeter compromising proper class I molar and canine relationship (Figure 7).
- L3: -8° of torque: In many cases where

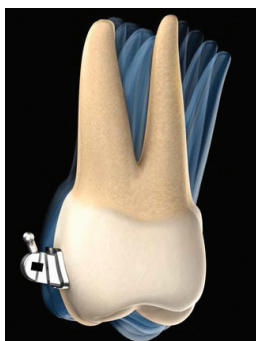
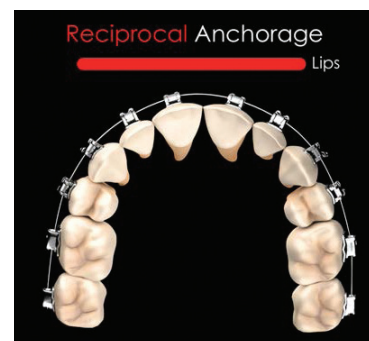
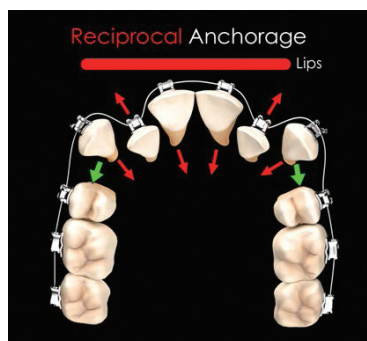


Figure 9: Highlight CCO Rx, torque for the upper molar

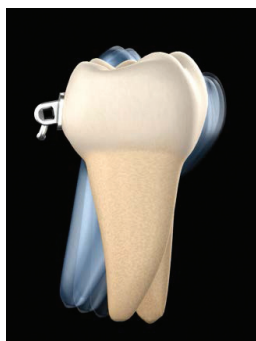

Figure 10: Highlight CCO Rx, torque for the lower molar



Figures 11A-11B: A diagram showing reciprocal forces developed when leveling and aligning (A) As the wire can move easily through the SLB and tubes, teeth move back to the space behind the canines rather than forward (B)

Wire Sequencing

Stage 1: Leveling and Aligning

Severe to Moderate Crowding			
.022 Slot	.018 Slot	Time	Goals
.014 Sentalloy***	.012 Sentalloy**	8-12 weeks	Complete leveling and aligning
.018 Sentalloy	.016 Sentalloy	8-12 weeks	Correct all rotations
.020 x .020 Bioforce®	.016 x .022 Bioforce	8-10 weeks	Maintain or Upright incisors Upright Pre Molars and Molars

*** In cases of minor crowding, you can skip the .014 Sentalloy when using an .022 bracket or the .012 Sentalloy when using an .018 bracket.

Stage 2: Working Stage

Non-Extraction			
.022 Slot	.018 Slot	Time	Goals
.021 x .028 Bioforce**	.018 x .025 Bioforce**	6-8 weeks	OJ/OB correction
.019 x .025 ss	.018 x .022 ss	30-40 weeks	Class II or III correction Close all remaining spaces Finish leveling the occlusal plane Arch coordination

Tables 1 and 2: Suggested wire sequence for Stage 1 and 2

the width of the maxillary and mandibular arches is normal, an excessive lingual crown torque (-11°), found in some Rx's, makes the coupling difficult with the U3. Therefore, the lower canine was upright to facilitate intercanine coupling (Figure 8).

- U6/U7: -14° / -20° of torque. Increased lingual crown torque, specifically for the second molar, facilitates the correction of the curve of Wilson, and therefore arch coordination, minimizing the need to add extra torque through a bend in the wire or by using auxiliaries such as palatal bars (Figure 9).

- L6/L7: -25° / -20° of torque. These values have been selected to prevent the commonly seen lingual rolling of lower molars (Figure 10).

Stages of treatment mechanics

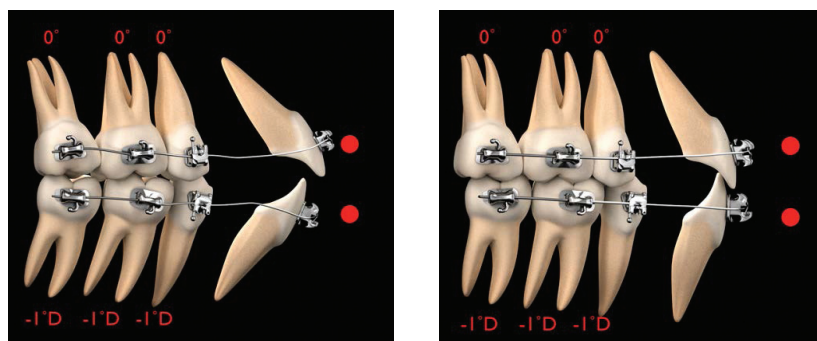
For didactic purposes, treatment mechanics has been usually divided in different stages, from three to seven depending on the author's preference. Simplicity is of paramount importance when teaching, and therefore, all the mechanics to be accomplished in orthodontic treatments with the CCO System can be divided into three stages: stage 1, leveling and alignment; stage 2, working stage; and stage 3, finishing stage. At each of these stages, there are specific movements of teeth that will occur and specific goals that have to be achieved before continuing to the next stage of treatment. It is important to emphasize that both the treatment outcome and its efficiency will be greatly improved if the orthodontist follows these stages.

Stage 1: Leveling and aligning

Leveling and aligning is a complex process in which all the crowns are moving at the same time and in different directions. As the teeth level and align, reciprocal forces between them develop, which can be of great help to guide the movements to our advantage (Figures 11A and 11B). Then, when possible, all teeth should be engaged from the beginning to obtain maximum efficiency of tooth movement. Usually at this stage, round small-diameter heat-activated wires such as a 0.014" Sentalloy® (Dentsply GAC) for severe crowding, or a 0.018" Sentalloy for moderate to minimum crowding, are preferred. It is always recommended to place crimpable stops to avoid undesirable movement of the wire, causing discomfort to the patient. These round wires can be in place for as long as 8 to 12 weeks before proceeding to the next wire, which usually is a 0.020" x 0.020" BioForce® (Dentsply GAC). The BioForce

wire is a low-deflection, heat-activated wire that works very well as a transitional wire from stage 1 to stage 2. The 0.020" x 0.020" BioForce corrects most of the rotations left by the previously used round wires and provides more stiffness to start leveling the curve of Spee and therefore flatten the occlusal plane. It is important to notice that even if treatment could be started with a rectangular or square heat-activated low-deflection wire, with the assumption of saving time and providing torque from the beginning of treatment, this is absolutely not recommended, because it may cause loss of posterior anchorage.

Since the only teeth with positive labial crown torque are the maxillary central and lateral incisors, and the mesial crown tip of the maxillary and mandibular canines is rather large, if treatment is started to resolve the crowding with a rectangular or square wire, labial crown torque is provided to the maxillary incisors and mesial crown tip to



Figures 12A-12B: Diagrams A and B show how round wires will allow molars and premolars to level, align, and upright, which will produce a “lasso” effect on the incisors. This will upright and sometimes even retract the protruded incisors

canines, which will increase the anchorage in the front part of the arch facilitating the loss of anchorage in the posterior part of the arch. This is critical in cases where the treatment plan calls for maximum retraction of the maxillary and/or mandibular incisors. Then, round wires will allow the molar and premolars to level, align, and upright, which will produce a “lasso” effect on the incisors that will upright and sometimes even retract (Figures 12A and 12B). The 0.020” x 0.020” BioForce will make the clip of the SLB active and thus start delivering torque; nonetheless, its strength is not sufficient to compromise the anchorage that has already been created with the round wires. Usually, after 8 to 10 weeks with the 0.020” x 0.020” BioForce, the stage 1 of leveling and aligning is finished, and it is the first time to evaluate bracket placement and debond/rebond as necessary. Then, the patient is ready to start stage 2, the working stage. Table 1 shows the most common wire sequence for this stage of treatment.

Stage 2: Working stage

At this stage, the maxillary and mandibular arches are coordinated, proper overbite and overjet are achieved, Class II or Class III are corrected, maxillary and mandibular midlines are aligned, extraction spaces are closed, and maxillary and mandibular occlusal planes are paralleled. Although most of these corrections happen simultaneously, some important points must be emphasized regarding arch coordination, management of the overbite/overjet, and the use of intermaxillary elastics.

Arch coordination

The maxillary and mandibular arch wires must be coordinated in order to obtain a stable occlusal intercuspation and proper

overjet. In an ideal intercuspation of a Class I, one-tooth to two-teeth occlusal scheme, the palatal cusps of the maxillary molars should intercuspate with the fossae and marginal ridges of mandibular molars; the buccal cusp of the mandibular premolars should intercuspate with the marginal ridges of the maxillary premolars; and the mandibular canines and incisors should intercuspate with marginal ridges of the maxillary canines and incisors. If this occlusal scheme occurs, it will then provide an overjet of 2 to 3 mm all around the arch from second molar to second molar. Then, the maxillary arch wire must be 2 to 3 mm wider than the mandibular arch wire. The arch wire coordination is done with the stainless steel wire. Even if they come preformed, the clinician should not rely on this, and should check them before insertion (Figure 13). Another important aspect of arch coordination is the effect that it has on the vertical dimension and the sagittal dimension. This specific issue will be reviewed in detail in part 2.

Overbite and overjet correction

An optimal overbite/overjet relationship does not have to be a certain predetermined number of millimeters. More important is the functional relationship they have. This means that the overbite/overjet should be compatible with a mutually protected occlusal scheme, and thus, allow for a proper anterior guidance in protrusion and lateral excursive movements. Although, as mentioned earlier, the number of millimeters is less important than the function, it is found that an optimal overbite is usually around 4 mm, and an optimal overjet is 2 to 3 mm. When diagnosing and treatment planning overbite/overjet problems, it is important to take the following key points into consideration: arch space management,

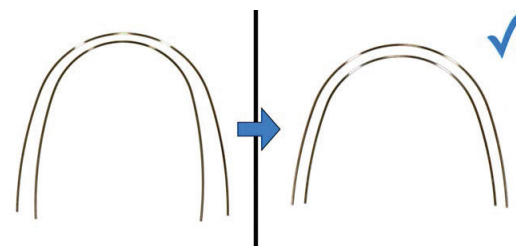


Figure 13: Shows arch coordination. Stainless steel arch wires must be coordinated for every patient. The upper wire should be 2 to 3 mm wider than the lower wire (B)

position of the mandible in centric relation, and relationship of the upper/lower incisors with the lips. Arch space management is important to understand because the SWA tends to flatten the curve of Spee, which requires space in the arch. If not enough space is available or created, the incisors will procline, increasing the arch perimeter. This incisor proclination will also decrease the overbite and may help, if it only occurs in the lower arch, to decrease the overjet. Flattening the maxillary and mandibular occlusal planes, proclining the incisors, can be of help in deep bite cases. When the incisors are not allowed to procline, space in the arch must be created. This is specifically important to avoid periodontal problems in cases with thin bone surrounding the incisor area. Up to 4 to 6 mm can be created with interproximal reduction of teeth, usually done on the incisors and, less often, the canines and premolars. If more than 6 mm of space is required, extraction of premolars could be indicated.

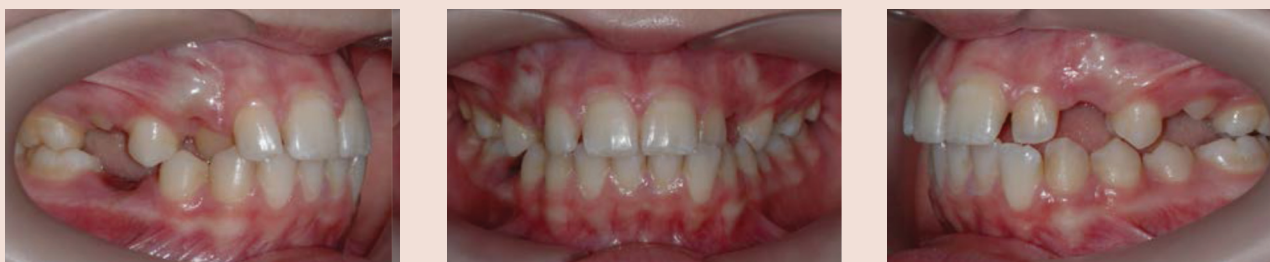Another important factor to consider when evaluating overbite/overjet problems is the position of the mandible. Often, differences between a maximum intercuspation (MIC) and centric relation (CR) can produce significant differences in the overbite/overjet relationship. And last, but by no means the least important, is the sagittal and vertical relationship of the maxillary and mandibular incisors with the lips. In an open bite case, should the orthodontist intrude the molars or extrude the incisors? In a deep bite case, should the clinician intrude the maxillary incisors, the lower, or both? These basic but very important questions can be answered through an understanding of the optimal relationship of the incisors with the lips. According to contemporary esthetic

Case example

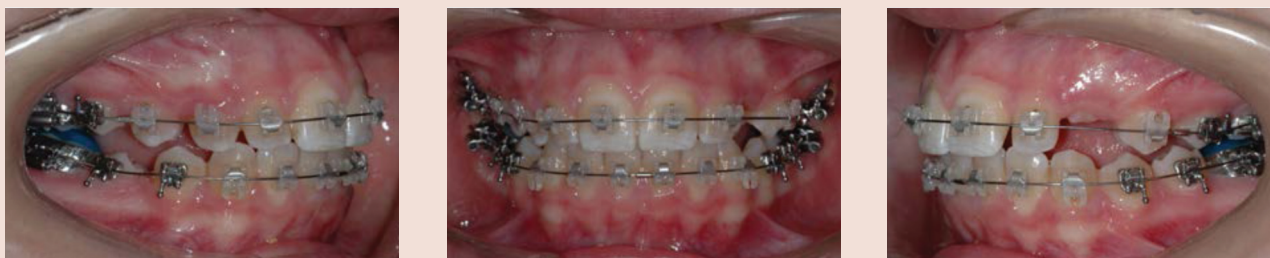A 12-year, 6-month-old Caucasian female consulted for orthodontic treatment due to a crossbite of the upper-right canine. Patient presented with a Class I malocclusion in late mixed dentition. Upper-right canine and upper-left lateral incisor were in crossbite. Midlines were off.



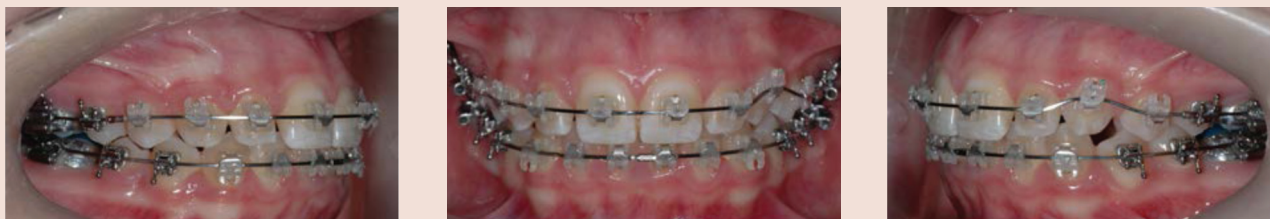Composite 1: Extraoral initial photos



Composite 2: Intraoral initial photos

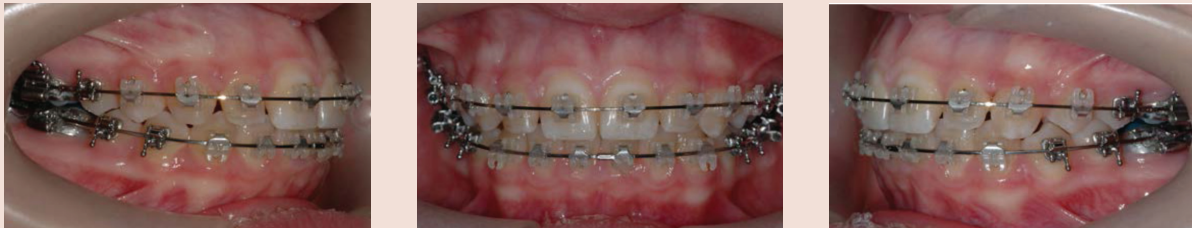

Composite 3: Mid course of the stage 1, leveling and aligning. Upper and lower .018" Sentalloy wires. The bite was temporarily open with composite buildup on the lower first molar to allow the canine to move buccally into alignment

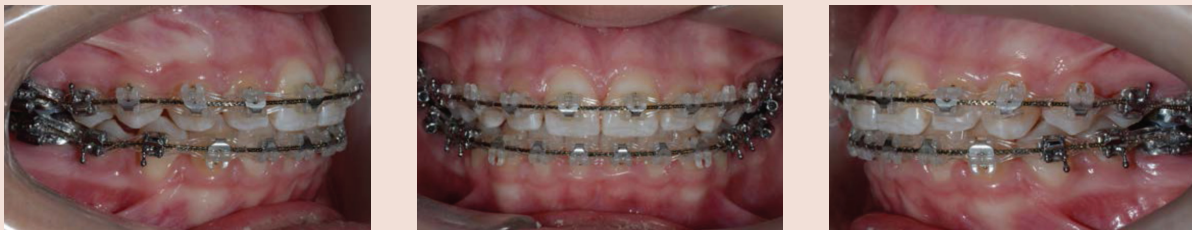

Composite 4: Upper .020" x .020" BioForce wire to finish leveling upper arch

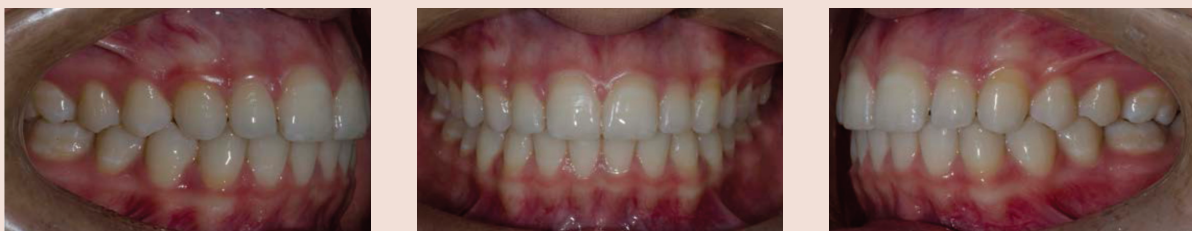Case example, continued



Composite 5: Upper and lower .019" x .025" SS coordinated arch wires. Notice parallelism of the upper and lower occlusal planes



Composite 6: Upper and lower .021" x .025" braided arch wires. At this time, triangular short vertical elastics are used to achieve optimal intercuspation



Composite 7: Intraoral final photos



Composite 8: Extraoral final photos

Stage 3: Finishing Stage

.022 Slot	.018 Slot	Time	Goals
.021 x .025 Braided	.018 x .025 Braided	4-6 weeks	Detail occlusion to achieve optimal intercuspation.

Table 3. Suggested wire sequence for Stage 3

trends and taking into account the aging process, for adolescents and young adults, maxillary incisors should have, at rest, an exposure of about 4 mm beyond the most inferior point of the upper lip known as upper stomion. As explained earlier, an optimal functional overbite should be about 4 mm. Now, if we put together the last two concepts, the incisal edge of the lower incisors should be at the same level with the most inferior point of the upper lip. Therefore, any vertical change of the incisors will affect not only the function through changes of the anterior guidance, but also the esthetics through the amount of tooth exposure. These anterior functional/esthetic references can help the clinician to determine the best strategies to correct overbite/overjet problems and will be of special importance for planning cases involving orthognathic surgery.

Intermaxillary elastics

Discretion is a good word to describe the use of intermaxillary elastics. I use them and like them, but it is important to understand how they are used to avoid problems. I usually do not use intermaxillary elastics in the following situations:

- Round wires
- Initial leveling and aligning, low-deflection wires
- To a terminal tooth, last tooth in the arch
- In the anterior part of the mouth to close open bites
- In the posterior part of the mouth to

correct crossbites

- For an extended period of time.
- I usually use intermaxillary elastics in the following situations:

- At the working and finishing stages
- On square or rectangular stainless steel wires
- On the buccal side of the mouth, short class II or III and/or triangular verticals

The three types of intermaxillary elastics this author commonly uses are 3/16" 4 oz., 6 oz., and 8 oz. elastics. Short means, in a Class II, for instance, from the maxillary canine to the mandibular second premolar in a non-extraction case and to the first mandibular molar in an extraction case.

Table 2 shows the most common wire sequence for non-extraction cases, at this stage of treatment. Wire sequence for extraction cases will be specifically covered in part 3).

Stage 3: Finishing stage

As I discussed previously, the active clip of the In-Ovation bracket system, pushes, and sits the wire onto the slot achieving optimal bracket expression with a 0.019" x 0.025" stainless wire. This is especially true in non-extraction cases with an average curve of Spee. However, in some cases the size and stiffness of a 0.021" x 0.025" stainless steel is indicated, such as in cases with a deep curve of Spee and extraction cases where minimum anchorage is required. Once the maxillary and mandibu-

lar occlusal planes are parallel and all the bracket slots are aligned, bracket position should be carefully checked for minor correction of tooth position, and therefore the second time of debond/rebond should be done. The last wire to be used is a stainless steel multibraided 0.021" x 0.025" arch wire. Although this wire is large enough to fill the slot of the bracket and then maintain the tip, torque, and offset of each tooth, its resilience permits both minor bracket repositioning and settling of the occlusion into an optimal intercuspation. It is important to notice that at this point in treatment, all the appliance interferences should be removed using a finishing carbide bur on a high-speed handpiece. With a thin articular paper, all contacts must be checked. Only tooth-tooth contacts should be allowed. All brackets, tubes, or band contacts must be removed to allow proper settling. Vertical triangular 3/16" elastics, either 6 oz. or 8 oz., are used to achieve proper intercuspation. These vertical elastics should not be used with the braided wire for more than 6 weeks to avoid rolling premolars and molars lingually, which can be detected not from the buccal but rather from the lingual, where premolars and/or molars will not be contacting. Finally, before removing the appliance, a complete assessment of the occlusal "end of treatment" goals should be performed. Table 3 shows the most common wire sequence for this stage of treatment. **OP**

REFERENCES

1. Andrews LF. Six keys to normal occlusion. *Am J Orthod.* 1972;62(3):296-309.
2. Andrews LF. The straight wire appliance origin, controversy, commentary. *J Clin Orthod.* 1976;10(2):99-114.
3. Andrews LF. The straight wire appliance explained and compared. *J Clin Orthod.* 1976;10(3):174-195.
4. Andrews LF. JCO interviews on the straight-wire appliance. *J Clin Orthod.* 1990;24:493-508.
5. Andrews LF. The straight-wire appliance. Extraction series brackets. *J Clin Orthod.* 1976;10(6):425-441.
6. Andrews LF. The straight-wire appliance. Extraction series brackets. *J Clin Orthod.* 1976;10(7):507-529.
7. Andrews LF. Fully programmed translation brackets. In: Andrews LF, ed. *Straight wire: the concept and appliance.* San Diego, CA:LA Wells; 1989.
8. Roth RH. Treatment mechanics for the straight wire appliance. In: Graber TM, Swain BF, eds. *Orthodontics: current principles and techniques.* St Louis, MO:Mosby; 1985.
9. McLaughlin RP, Bennett JC, Trevisi HD. *Systemized orthodontic treatment mechanics.* St Louis, MO:Mosby; 2001.
10. Moesi B, Dyer F, Benson PE. Roth versus MBT: does bracket prescription have an effect on the subjective outcome of pre-adjusted edgewise treatment? [published online ahead of print Nov 2, 2011] *Eur J Orthod.*
11. Woodside DG, Berger JL, Hanson GH. Self-ligation orthodontics with the SPEED appliance. In: Graber TM, Vanarsdall RL and Vig KW, eds. *Orthodontics: current principles and techniques.* St Louis, MO:Mosby; 2005.
12. Chen SS, Greenlee GM, Kim JE, Smith CL, Huang GJ. Systematic review of self-ligating brackets. *Am J Orthod Dentofacial Orthop.* 2010;137(6):726.
13. Gick MR, Nóbrega C, Benetti JJ, Jakob SR, Zucchi TU and Arsati F. Comparative study of the movement of torque induced by systems self-ligation and conventional. *Orthodontic Science and Practice.* 2012;5(17):37-46.
14. Raphael E, Sandrik JL, Klapper L. Rotation of rectangular wire in rectangular molar tubes. Part I. *Am J Orthod.* 1981;80(2):136-144.
15. Lang RL, Sandrik JL, Klapper L. Rotation of rectangular wire in rectangular molar tubes. Part II. Pretorqued molar tubes. *Am J Orthod.* 1982;81(1):22-31.