

Complete Clinical Orthodontics: Treatment mechanics: part 2

Dr. Antonino Secchi discusses bracket placement, arch coordination, and leveling the occlusal plane in conjunction with the CCO System

Introduction

In part 1 of this three-article series, we reviewed the core concepts of the Complete Clinical Orthodontics (CCO) system, how we integrated the straight-wire appliance (SWA) with self-ligation to improve control and efficiency, and the rationale for the recently developed CCO prescription, as well as the three stages of treatment mechanics. Specifically, we reviewed the goals and objectives of each stage of treatment emphasizing the more appropriate wire sequence to facilitate accomplishing these objectives. In this article, we will further review some areas that we think are very important in mechanics and that usually require a more in-depth analysis. We will specifically review bracket placement, arch coordination, and leveling the occlusal plane, as well as their effect on the vertical plane. We cannot emphasize enough how important proper bracket placement is for the progress as well as finishing of our cases. Arch coordination and leveling the occlusal plane are two goals to be accomplished at the working stage. Often overlooked, these two concepts have a direct relationship with treatment of vertical problems.¹

Educational aims and objectives

This article aims to continue the discussion of the CCO System and explore mechanics in greater depth, specifically reviewing bracket placement, arch coordination, and leveling the occlusal plane, as well as the effect on the vertical plane.

Expected outcomes

Correctly answering the questions on page XX, worth 2 hours of CE, will demonstrate the reader can:

- Identify optimal bracket placement.
- Realize the various aspects of arch coordination.
- Recognize the direct relationship between leveling the occlusal plane and vertical problems.
- Discuss how the maxillary and mandibular occlusal planes can be managed to correct open bite as well as deep bite problems.

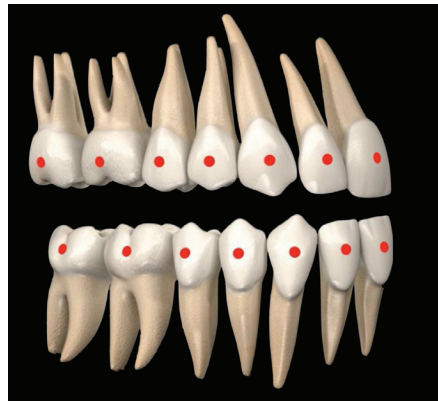

Figure 1: Diagram with the correct place of the FA point for each tooth in both the maxilla and mandible

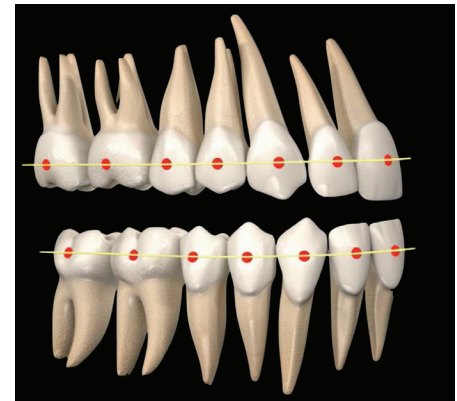


Figure 2: Diagram with all FA points connected with a line as if it were a straight arch wire

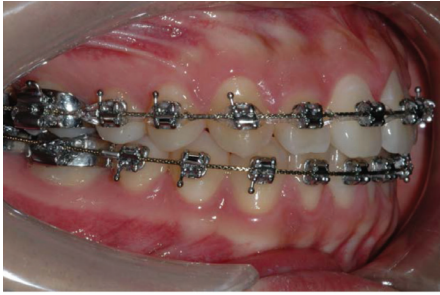
Antonino G. Secchi, DMD, MS, is a clinical assistant professor and former clinical director of the Department of Orthodontics at the University of Pennsylvania. Dr. Secchi received his DMD, Certificate in Orthodontics, and a Master of Science Degree in Oral Biology from the University of Pennsylvania. He is a Diplomate of the American Board of Orthodontics and member of the Edward H. Angle Society of Orthodontists. At the University of Pennsylvania, he has developed and implemented courses on Orthodontic Treatment Mechanics, Straight Wire Appliance Systems, and Functional Occlusion in Orthodontics for postdoctoral orthodontic residents. Dr. Secchi wrote the chapter "Contemporary Mechanics Using the Straight Wire Appliance" for the latest edition of the Graber/Vanarsdall/Vig orthodontic textbook. He also received the 2005 David C. Hamilton Orthodontic Research Award from the Pennsylvania Association of Orthodontists (PAO) and the 2010 Outstanding Teacher Award from the Department of Orthodontics of the University of Pennsylvania. Dr. Secchi is the founder of the "Complete Clinical Orthodontics System" (CCO System™), which he teaches to orthodontists throughout the world. He also maintains an active orthodontic practice in Philadelphia and Devon, Pennsylvania.

Optimal bracket placement

Assuming we have the right appliance, the next most important factor when working with a SWA is bracket position. As Andrews described more than 40 years ago, the brackets should be placed at the FA point.^{2,3} The FA point is the middle of the clinical crown occlusogingivally and mesiodistally, and follows the long axis of the crown for each tooth in the mouth (Figure 1). When all the maxillary and mandibular teeth are perfectly leveled and aligned, the FA points of all the teeth should be aligned and connected through a straight line (Figure 2). It follows that it should be the orthodontist's goal to place each bracket in agreement with the FA point (Figure 3), so at the end of treatment, all the teeth can be perfectly leveled and aligned with a straight arch wire (Figure 4). Here

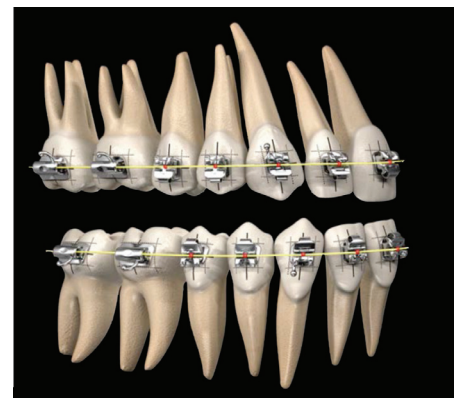
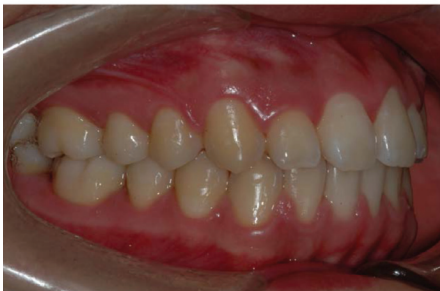
Figure 3: Diagram with brackets and tubes placed in agreement with the FA point for each tooth in both the maxilla and mandible



Figures 4-4B: 4A: Clinical photo of a case just before removing the appliances. Notice the alignment of the appliance as well as the teeth in both the maxilla and the mandible. Each tooth is in the optimal position, brackets and tubes are in agreement with the FA point of each crown, and a straight wire from second molar to second molar is connecting all brackets and tubes. 4B: The same case just after removing the appliance

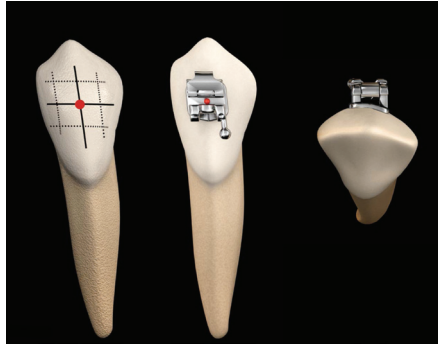


Figure 5: Labial and occlusal diagram of a lower canine with the references for ideal bracket placement. Notice that the most prominent part of the labial side of the canine is a little offset to the mesial

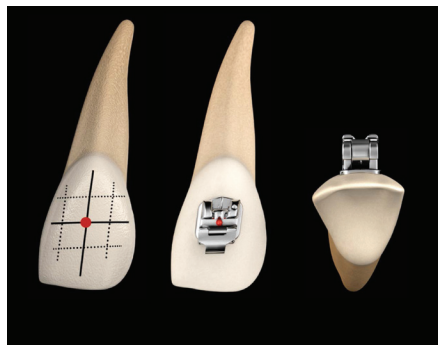


Figure 7: Labial and occlusal diagram of an upper lateral incisor with the references for ideal bracket placement

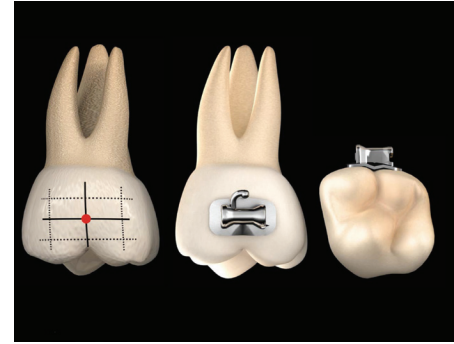


Figure 6: Labial and occlusal diagram of an upper first molar with references for ideal bracket placement. Notice that the long axis of the clinical crown for molars is the buccal groove

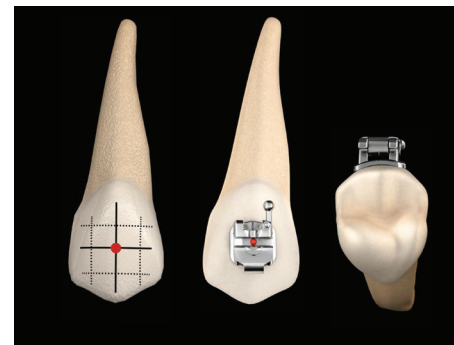


Figure 8: Labial and occlusal diagram of an upper premolar with the references for ideal bracket placement

is where the orthodontist's understanding and dexterity will be of great value. The final results of techniques requiring wire bending are affected by the quality and precision of each bend; similarly, the precision of bracket placement affects the final outcome when using a SWA. By this logic, you "start to finish" your cases the day you place the brackets! This is why an important percentage of problems that orthodontists experience toward the end of active treatment—such as marginal ridge discrepancies, difficulty correcting rotations, lack of root parallelism, and, ultimately, less than ideal tooth position—are due to incorrect bracket placement.

Because all the brackets are working at the same time through the wire, one misplaced bracket will automatically affect the adjacent brackets. If more than one bracket is misplaced, the problem will increase and become more noticeable as the leveling and alignment progresses. This issue, if not corrected, can prevent the orthodontist from finishing the case in an optimal and efficient way.

We will focus on describing the teeth that usually cause more problems for clinicians, which will be based upon the

following important concepts:

- We believe that trained clinicians are able to place brackets consistently at the FA point with their own eyes and without any additional aids but their own eyes.
- The use of any gauge as an aid to position the brackets is not necessary. In fact, to use any predetermined height from the incisal edge to locate the brackets may cause problems and literally negates the use of the FA point, which is one of the fundamental concepts of the SWA development. However, it is important to take into account the individual patient's tooth morphology such as shorter crowns due to excessive gingival tissue, worn teeth, or fractured teeth that eventually will be restored. In some of these situations, bracket placement should be adjusted accordingly, and as a result, the bracket will look either more incisally or gingivally than the apparent middle of the clinical crown on that particular tooth.

Although the FA point and long axis of clinical crowns are key to bracket position, there are a few considerations that will facilitate bracket placement on

teeth that usually present challenges for the orthodontist, such as the upper and lower canines, upper and lower molars, and sometimes upper lateral incisors and premolars.

- Canines (Figure 5): The long axis of the upper and lower canines, which is also the most convex part of the labial surface, is located more mesial than the true mesiodistal center of the tooth; therefore, the FA point looks a little bit more mesial than the dead center of the tooth. If you err and place the bracket on the center of the crown mesiodistally, the canine will rotate mesially.

- Molars (Figure 6): The landmark that Andrews used as the long axis of the clinical crown for the molar is the buccal groove. The FA point lies along the buccal groove and midway occlusogingivally. It is important to realize that the center of the tube mesiodistally should be in agreement with the FA point. As some manufacturers have reduced the mesiodistal length of tubes, orthodontists have started positioning tubes too far mesial causing an over rotation of the molars to the distal.

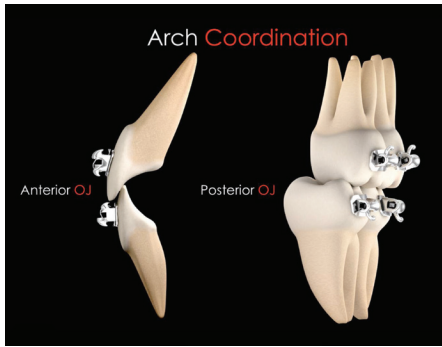
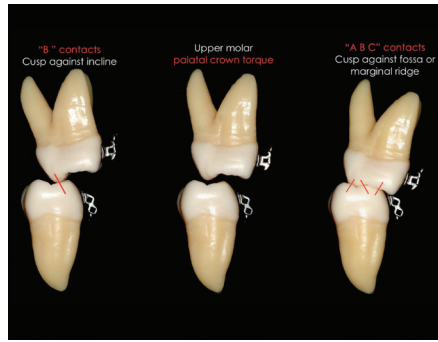
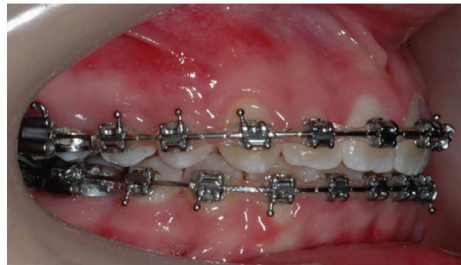
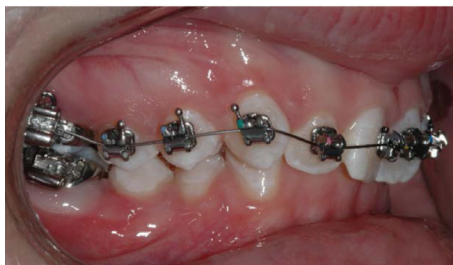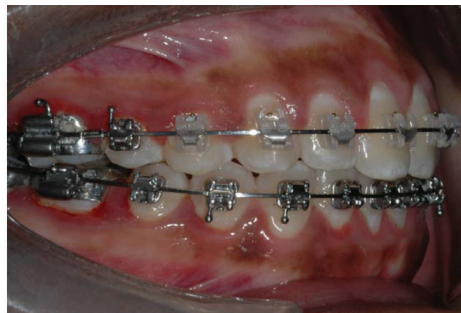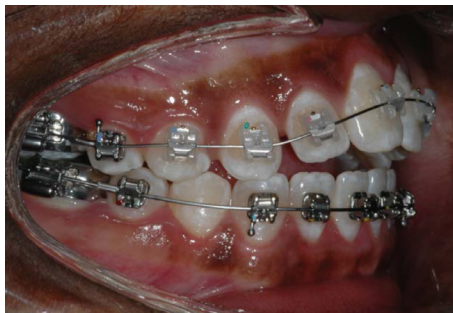


Figure 9: Diagram with the optimal occlusal relationship of posterior and anterior teeth. When in optimal occlusion, there is an overjet of 2-3 mm from second molar to second molar



Figures 10A-10C: 10A: The maxillary molar buccally is inclined producing a premature contact. This can increase the posterior vertical dimension, which could produce an anterior open bite. 10B: Maxillary molar with proper palatal crown torque. 10C: The optimal molar vertical relationship



Figures 11A-11B: 11A: Case with an anterior open bite at the beginning of treatment and then after the maxillary and mandibular occlusal planes have been leveled. 11B: Case with a deep overbite at the beginning of treatment and then after the maxillary and mandibular occlusal planes have been leveled

- Upper lateral incisor (Figure 7): After the third molars, upper lateral incisors are the teeth with more problems regarding size and shape. This makes it difficult to determine the long axis of the crown from the buccal. It is wise to use the mirror to look at the lingual surface of the incisor and then extend the long axis of the clinical crown from the lingual to the buccal.

- Premolars (Figure 8): Usually premolars, specifically second premolars, represent a challenge at the time of bonding due to lack of direct vision. Then it is advisable to look with the mirror from the occlusal and the buccal to locate the FA point and the long axis of the clinical crown.

Arch coordination

As discussed in part 1 of this series of articles, the maxillary and mandibular arch wires must be coordinated in order to obtain a proper occlusal intercuspation. In an ideal intercuspation of a Class I, one-tooth to two-teeth occlusal scheme, the palatal cusps of the maxillary molars should intercuspate with the fossae and marginal ridges of mandibular molars, the buccal cusp of the mandibular premolars should intercuspate with the marginal ridges of the maxillary premolars, and the mandibular canines and incisors should intercuspate with marginal ridges of the maxillary canines and incisors. If this occlusal scheme occurs, it will then provide

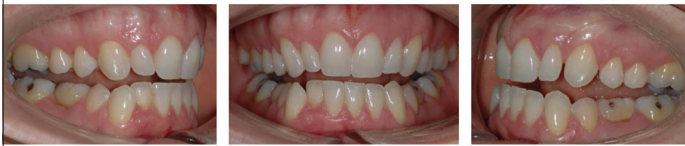an overjet of 2 to 3 mm all around the arch from second molar to second molar. Then, as seen in Figure 9, the maxillary brackets and tubes are 2 to 3 mm more buccal than the mandibular brackets and tubes and therefore, the maxillary arch wire must be 2 to 3 mm wider than the mandibular arch wire. The arch wire coordination is done at the working stage using a .019" x .025" stainless steel (SS) wire. Even if they come preformed, the clinician should not rely on that, and check them before insertion. Another important aspect of arch coordination is the effect that it has on both the vertical and sagittal dimensions.⁴ The maxillary teeth should be upright and centered in the alveolar/basal bone and coordinated with the mandibular teeth, which should also be upright and centered in the alveolar/basal bone to obtain a proper intercuspation. Often, this is not the case, and we find maxillary molars buccally inclined, also referred as an accentuated Curve of Wilson, which can produce contacts between the palatal cusp of maxillary molars and the inclines of the mandibular molars, also known as "B contacts" (Figure 10). This decreases the overbite and sometimes produces even an open bite (vertical problem), which in turn can produce a downward and backward movement of the mandible (sagittal problem). This phenomenon is due to the lack of palatal crown torque of the maxillary molars. Depending on the amount of palatal crown torque needed for the maxillary molars to level the curve of Wilson, we suggest the following solutions:

1. For minor to moderate problems with torque, use molar tubes with the CCO Rx (-14° of palatal crown torque for the upper first molars and -20° of palatal crown torque for the upper second molars) and a .019" x .025" SS wire.
2. For severe problems with torque, a transpalatal bar (TPB) is suggested. TPB can effectively deliver palatal crown torque to maxillary molars.

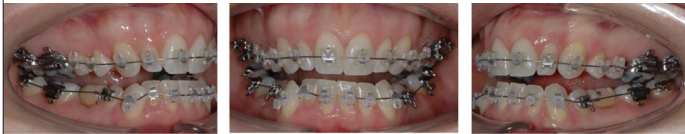Leveling the occlusal plane

Leveling the maxillary and mandibular occlusal planes to make them almost parallel to each other is a treatment goal in our system. Whether the case started with divergent maxillary and mandibular occlusal planes (e.g., open bite cases) or with convergent maxillary and mandibular occlusal planes (e.g., deep bite cases), at

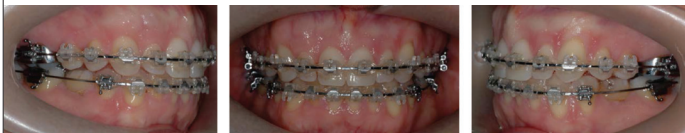Case Example 1



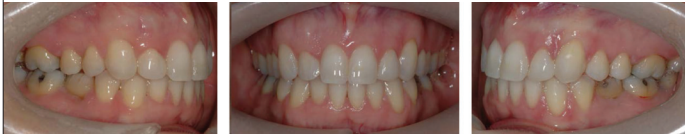Composite 1: Initial intraoral photos



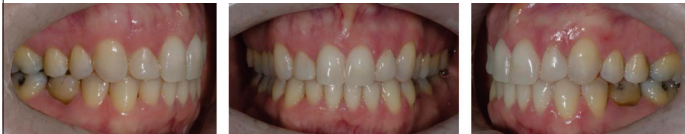Composite 2: Beginning of stage 1, leveling and aligning stage. Upper and lower .014" Sentalloy wires



Composite 3: At the end of stage 2, working stage. Upper and lower .019" x .025" SS. Arches are coordinated and maxillary and mandibular occlusal planes are leveled and parallel



Composite 4: Final intraoral photos



Composite 5: 1.5 years post-treatment

42-year-old Caucasian female consulted for orthodontic treatment and was referred by her general dentist due to an open bite. Patient presented with congenitally missing lower second premolars, anterior open bite (only contacting on second molars), small lateral incisors, and history of temporomandibular disorder. She had been wearing a maxillary splint for the last 8 months. At the time of the consultation, she was asymptomatic

the end of treatment, both the maxillary and mandibular occlusal planes should be level (Figure 11). It is very important to realize the direct relationship between leveling the occlusal plane and vertical problems. We will explain how the maxillary and mandibular occlusal planes can be managed to correct open bite as well as deep bite problems.

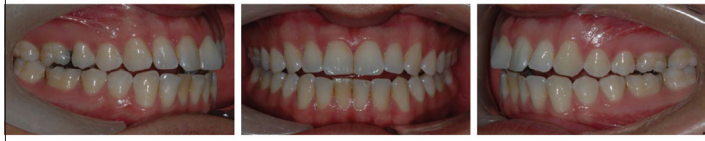Vertical problems: open bites

To apply the most efficient treatment mechanics, it is very important to understand the cause of the problem; in other words, a proper diagnosis is required! Some anterior open bites are the result of misaligned posterior teeth affecting the proper posterior overbite. If the vertical dimension increases at the molar level, the anterior overbite will be affected. If the posterior overbite is not corrected, it will be very difficult to correct the anterior overbite.

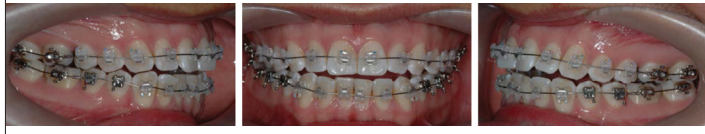Case example 1 shows an anterior open bite due to an arch coordination problem. The maxillary second molars are buccally positioned causing a primary contact that increases the posterior vertical dimension. We corrected this case by leveling the Curve of Wilson providing proper torque to maxillary molars so the molars' palatal cusps could seat on the central fossae of the mandibular molars. As the posterior overbite was corrected, the maxillary and mandibular occlusal planes became parallel, and the anterior open bite closed achieving a proper anterior overbite.

Case example 2 shows another anterior open bite. In this case, the problem is the difference between the tipping of the maxillary first and second molars. The maxillary first molars are tipped mesially, leaving the distal cusps hanging down. We corrected this case by leveling both the first and second maxillary molars. We started

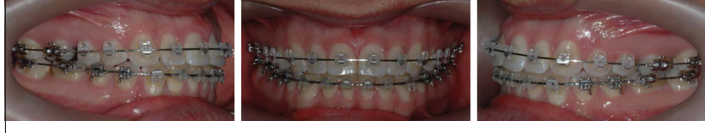Case Example 2



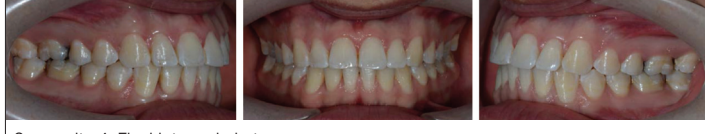Composite 1: Initial intraoral photos



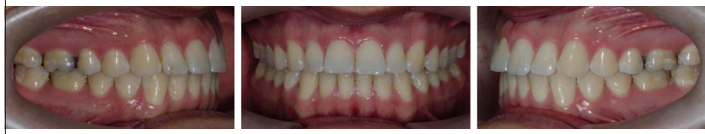Composite 2: Beginning of stage 1, leveling and aligning stage. Upper and lower .014" Sentalloy wires



Composite 3: At the end of stage 2, working stage. Upper and lower .019" x .025" SS. Arches are coordinated and maxillary and mandibular occlusal planes are leveled and parallel



Composite 4: Final intraoral photos



Composite 5: 1 year post-treatment

23-year-old Caucasian male consulted for orthodontic treatment due to an anterior open bite. Patient presented with a Class I malocclusion with an anterior open bite from first molar to first molar

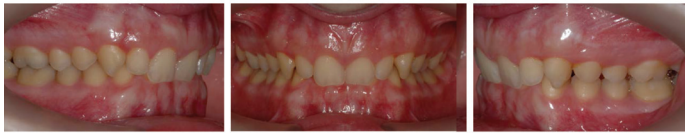with two occlusal planes in the maxilla: one for the second molar and one for the first molar along with the rest of the teeth. We finished with only one leveled occlusal plane for the maxilla, which was parallel to the mandibular occlusal plane.

It is important to notice that in both of these cases, the second molars were part of the problem as well as the solution. Therefore, we strongly suggest that second molars should always be included as part of the comprehensive correction. Although some orthodontists believe that leveling second molars may open the bite, we have seen so only in a few cases and just temporarily. Once the second molars are completely leveled and coordinated, it will actually help in correcting the vertical problem.

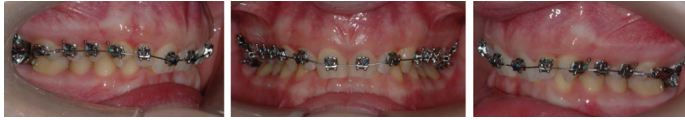Vertical problems: deep bite

It is very common to find inadequate torque

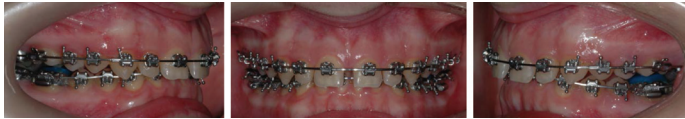Case Example 3



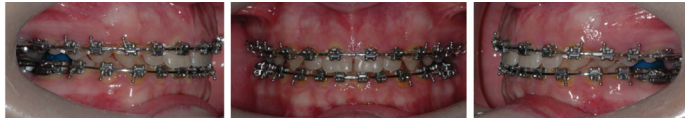Composite 1: Initial intraoral photos



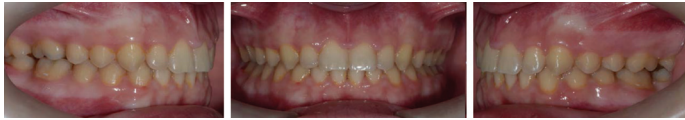Composite 2: Beginning of stage 1, leveling and aligning stage. Upper .014" Sentalloy wires



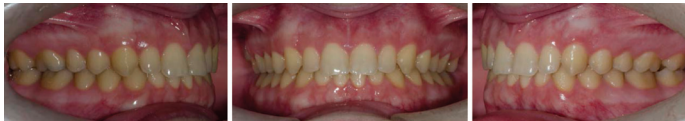Composite 3: At the beginning of stage 2, working stage. Upper and lower .019" x .025" SS. Reverse curve of Spee was added to the lower wire. Short Class II, 6 oz elastics were used



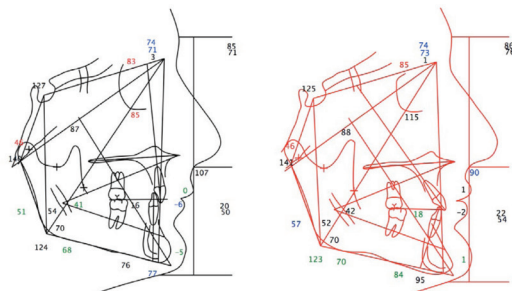
Composite 4: At the end of stage 2, working stage. Upper and lower .019" x .025" SS. Spaces are consolidated, arches are coordinated, and maxillary and mandibular occlusal planes are leveled and parallel



Composite 5: Final intraoral photos



Composite 6: 1 year post-treatment



Composite 7

15-year-old Caucasian male consulted for orthodontic treatment and was referred by his general dentist. Patient presented with a Class II end-on malocclusion with a deep over bite. Upper and lower incisors were severely retroclined

of maxillary and mandibular anterior teeth in deep bite cases. The long axes of anterior teeth are often excessively vertical over the basal bone. Also, the Curve of Spee is accentuated and, in some cases, severely deep. In this type of malocclusions, it is mandatory to first correct the inclination of maxillary anterior teeth and to create space in the sagittal plane to unravel the mandibular arch and level the Curve of

Spee. By leveling the maxillary arch and providing optimal buccal crown torque to all four incisors as well as leveling the mandibular arch and flattening the curve of Spee, we are once again leveling and paralleling the maxillary and mandibular occlusal planes.

Case example 3 shows a Class II end-on, deep bite malocclusion. As one can appreciate from pretreatment

cephalometric values, the maxillary and mandibular incisors are severely upright. We treated this case by leveling and aligning the maxillary arch first. Once we leveled the maxillary occlusal plane and achieved the proper torque on all four incisors, we started leveling and aligning the lower arch. At the working stage, reverse curve of Spee was added to a .019" x .025" SS archwire and short Class II elastics were used. It is important to point out that in cases with severe retroclination of maxillary incisors, spaces will appear between all four incisors as these teeth procline buccally. We strongly suggest leaving these spaces until the lower arch has been leveled, and then close all spaces together. With this approach, we do not risk losing torque of the maxillary anterior teeth by closing the spaces too soon. Post-treatment cephalometric values show the corrected inclination of maxillary and mandibular incisors.

Conclusion

Correct bracket placement will facilitate the flow of the case at each stage of treatment ultimately allowing an optimal finishing. The clinician should know and be familiar with the proper references and tooth landmarks used for correct bracket placement. The time and effort spent on proper bracket placement at the beginning of treatment will definitely pay off during the course of treatment as well as at the end of it. Arch coordination and leveling the occlusal plane are two very important goals to achieve at the working stage. Unfortunately, these goals are often overlooked. Both arch coordination and leveling the occlusal plane also have important implications in the treatment of vertical problems. The treatment of some open bite cases as well as some deep bite cases can be effectively managed by proper arch coordination and leveling the occlusal plane. **OP**

REFERENCES

1. Secchi, AG: *CCO Manual on Treatment Mechanics*. 2nd ed. Islandia, NY; 2012.
2. Andrews LF. The six keys to normal occlusion. *Am J Orthod*. 1972;62:296-309.
3. Andrews LF. The straight-wire appliance, origin, controversy, commentary. *J Clin Orthod*. 1976;10(2):99-114.
4. Secchi AG, Ayala J. Contemporary treatment mechanics using the straight wire appliance. In: Graber TM, Vanarsdall RL, Vig K, eds. *Orthodontics: current principles and techniques*. 5th ed. St Louis, MO: Mosby; 2011:561-80.